Technical Bulletin

Comparative Anatomy of the Pig

M. Michael Swindle, DVM, Professor and Chairman, Department of Comparative Medicine, Medical University of SC, Charleston, SC 29425

With the increasing use of swine as models in biomedical and surgical research, investigators have encountered difficulty with the species because of physiologic and anatomic variations from more traditional large animal models, such as the dog.[1,2] The problems encountered in anesthesia and surgery of swine have been addressed in previous publications.[1,3] Several textbooks address the anatomy of the pig in detail.[1,4-8] This article seeks to provide a concise, illustrated guide to the anatomy of the pig with emphasis on its variations from the dog and its similarities to humans.

Cardiovascular System

The heart is typical of most mammals with a few variations. The distribution of blood supply by the coronary artery system is almost identical to that of humans.[2,9] The major anatomic variation from other mammalian species is the presence of the large left azygos vein, which enters the coronary sinus (Fig. 1). In other mammals, hemiazygos vein enters the precava. Histologically, the pig has more prominent Purkinje cells and a more prominent vasa vasorum in the aortic wall than is seen in the dog.

The peripheral vasculature has some variations from the dog. The external jugular vein is relatively large in the pig, but not superficial as in other common lab animals. The vein is located medial to a line drawn from the angle of the mandible to the point of the shoulder, at the same depth as the sommon carotid artery and internal jugular vein. The cephalic vein is quite prominent and superficial as it crosses the neck at the level of thoracic inlet. A review of peripheral vascular injection sites has been published.[3]

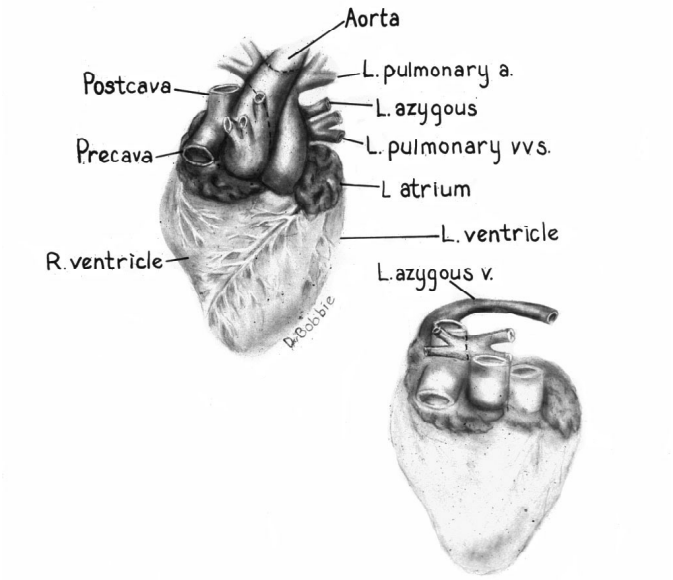

Figure 1. Cranial view of the porcine heart showing the relationships of the blood vessels at the base of the heart. In the bottom view, the great vessels have been severed to reveal the leftazygos vein.

Gastrointestinal System

Although the physiology of digestion in swine is remarkably like that in humans,[2,7] the anatomy is quite different from other mammals (Fig. 2). The stomach is ypical of monogastric species except for a prominent muscular outpouching, the torus pyloricus, at the level of pylorus. The intestinal tract is quite long, measuring approximately 15 times the length of the body.[6] The mesenteric vessels of the small intestine form vascular arcades in the muscularis mucosa of the intestine and not in the mesentery, as in other mammals.

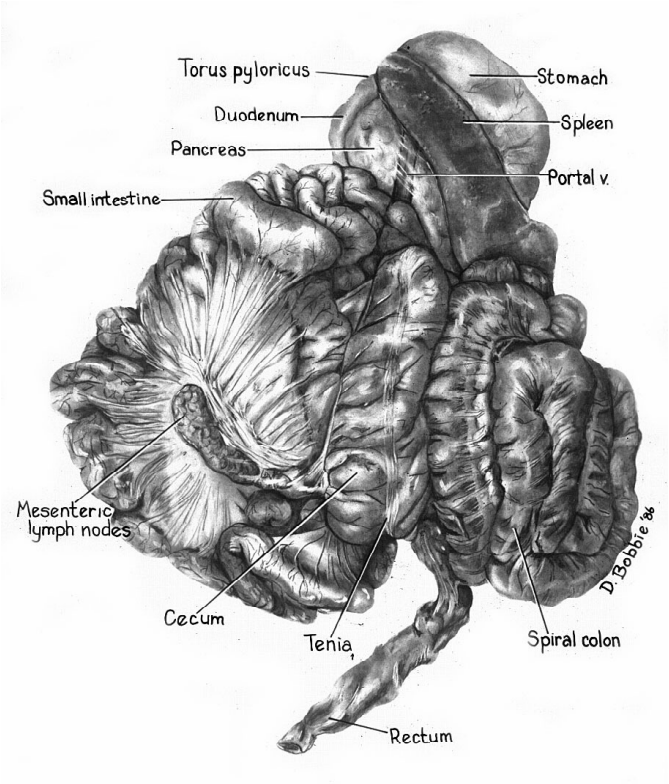

Figure 2. Ventral view of the abdominal viscera

The large intestine of the pig is quite different anatomically from that of other common laboratory animals. The cecum, the ascending and transverse colon and the proximal portion of the descending colon are arranged in a series of centrifugal and centripetal coils in the left upper quadrant of the abdomen. This structure is known as the spiral colon. The cecum has three longitudinal muscular

© 2008 Sinclair Research Center, Inc. All Rights Reserved.

www.sinclairresearch.com
info@sinclairresearch.com
PO Box 658 Columbia, MO 65205
Tel: (573)387-4400 ▪ Fax: (573)387-4404

M. Michael Swindle, DVM, Professor and Chairman, Department of Comparative Medicine, Medical University of SC, Charleston, SC 29425

bands (tenia) and the proximal portion of the spiral colon has two bands. These result in a series of sacculation (haustra).

Pancreas

The pancreas is related to the proximal duodenum in the usual manner, with a single pancreatic duct entering the duodenal lumen distal to and separate from the common bile duct. The pancreas is more loosely attached to the blood supply of the duodenum than in the dog, facilitating dissection during a pancreatectomy.[10] However, the body of the pancreas separates in the two lobes that encompass the portal vein, and a portion of the pancreatic lobes is retro peritoneal, as in humans. Histologically, the pancreas is quite lobulated and fatty.

Kidney

The left kidney is more cranial than the right (Fig. 3). The intrarenal anatomy of the kidney is closer to man than in any other commonly used laboratory animals. The pig has a true multireniculate, multipapillate kidney with true calices as in humans.[11] An important difference and consideration for intratenal surgery is that the avascular plane of the kidney is transverse in swine, not longitudinal as in dogs and humans.

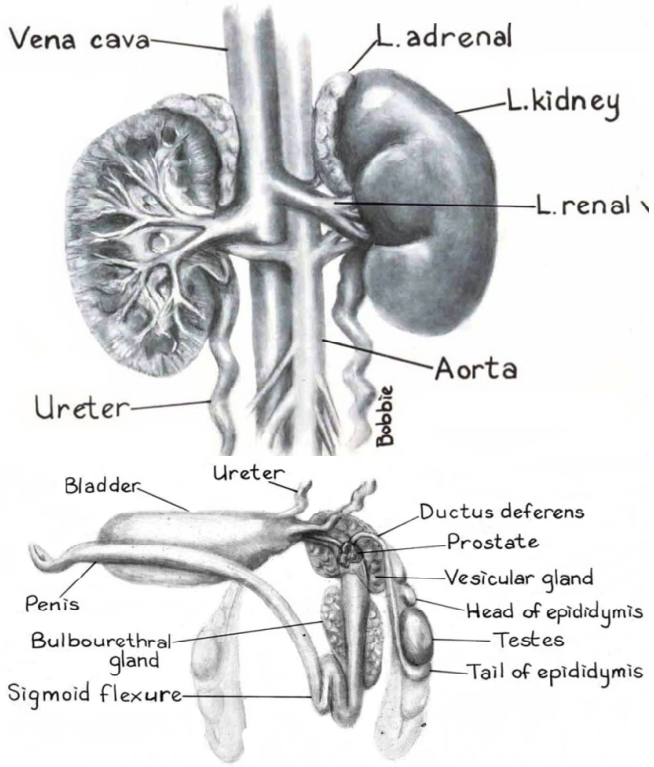

Figure 3. Top: Ventral view of the kidneys and adrenal glands. The right kidney has been dissected to show the internal renal structures and the vascular division of the renal parenchyma. Bottom: Ventral view of the male urogenital system with the bladder displaced laterally.

Male Reproductive System

The boar has a fibromuscular penis with a sigmoid flexure that aids in erection, instead of prominent rectile tissue (Fig. 3). The tip of the penis is corkscrew-ficult, if not impossible in most individuals, to pass a urinary catheter. The preputial diverticulum on the ventral surface of the abdomen is filled with necrotic debris and residual urine and must be avoided or cleaned when performing abdominal surgery. Accessory sex glands of the boar include seminal vesicles, a prostate gland, and buldourethral glands in an arrangement similar to humans.

Female Reproductive System

The female reproductive tract has a typical bicornuate uterus like other species that bear litters. The Fallopian tubes are prominent and tortuous making them readily accessible to surgical procedures. Histologically, they are similar to those of humans.[12]

Endocrine System

The right adrenal gland has a close attachment to the caudal vena cava and is not readily extirpated by surgical means (Fig. 3). The thyroid gland is located on the ventral midline of the trachea at the level of thoracic inlet instead of being associated with the larynx as in most species (Fig. 4). The thymus extends from the thorax into the neck cranially to the level of the larynx in young animals. Even as the gland shrinks with age, it does not tend to become completely thoracic in

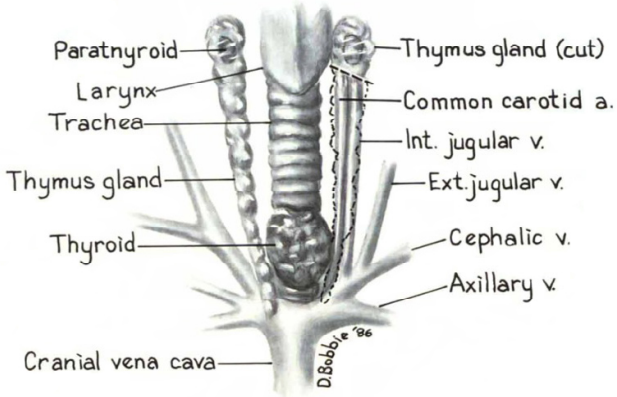

Figure 4. Ventral view of the neck with the musculature removed to show the relationship of the vasculature and endocrine structures to the larynx and trachea.

location. The single pair of the parathyroid glands are closely related to the thymus rather than to the thyroid gland. Their location is variable depending on the age of the pig, but they can generally

© 2008 Sinclair Research Center, Inc. All Rights Reserved.

www.sinclairresearch.com
info@sinclairresearch.com
PO Box 658 Columbia, MO 65205
Tel: (573)387-4400 ▪ Fax: (573)387-4404

M. Michael Swindle, DVM, Professor and Chairman, Department of Comparative Medicine, Medical University of SC, Charleston, SC 29425

be found in the first fascial plane medial to the thymus at it cranial end.

Lymphatic System

The lymph nodes are histologically unique in having an inversion of the cortex and medulla. The germinal centers are more central than in other species, with the outer region being more similar to the medulla. The spleen is more tightly attached to the stomach by the short gastric blood vessels and therefore is not as pedunculate an organ as it is in the dog.

Conclusion

This article by no means provides a complete guide to the dissection of the pig. More complete textbooks should be consulted prior to performing complex surgical procedures.[1-8] It must be remembered, however that standard textbooks of veterinary anatomy[4-7] generally refer adult commercial breeds of swine, but most experimental surgery is performed using young swine or miniature breeds in which organ size and location may differ significantly. Other research-oriented references are geared towards these differences.[1-3,7-12]

References

1. Swindle, M.M. and Bobbie, D.L., 1983, *Basic Surgical Exercises Using Swine*, Praeger Publishers, New York.
2. Swindle, M.M., 1984, *Swine as Replacement for Dogs in the Surgical Teaching and Research Laboratory*, Lab. Anim. Sci. 34:383
3. Swindle, M.M., 1985, *Anesthesia in Swine*, Charles River Tech. Bull. 3:3.
4. Sack, W.O., 1982, *Essentials of Pig Anatomy*, Veterinary Textbooks, Ithaca, New York.
5. St. Clair, L.E., 1981, *Anatomy*, in Lemon, A.D., Glock, R.D., Mengeling, W.L., Penny, R.H.C., Scholl, E., and Straw, B. (editors), *Diseases of Swine*, 5th ed., Iowa State University Press, Ames, Iowa
6. Getty, R. (editor), 1975, *Sisson and Grossman's The Anatomy of the Domestic Animals*—Porcine, Vol. 2, W.B. Saunders, Philadelphia
7. Pond, W.G. and Houpt, K.A., 1978, *The Biology of the Pig*, Comstock Publishing Associates, Ithaca, New York.
8. Gilbert, S.G., 1966. *Pictorial Anatomy of the Fetal Pig*, 2nd ed., University of Washington Press, Seattle.
9. Peng, C.F., et al., 1983, *The Adverse Effect of Systemic Hypertension Following Myocardial Reperfusion*, J. Surg. Res. 34:59
10. Koyama, I., et al., in press, *Pancreatic Allotransplantation with Roux-en-Y Jejunal Diversion in Swine: Its Technical Aspects*, in Tumbleson, M.E. (editor) *Swine in Biomedical Research*, Plenum Publishers.
11. Boyce, W.H., et al., 1979, *Management of the Papillae During Intrarenal Surgery*, Trans. Am. Assoc. Genito-Urinary Surg., 71:76
12. Rock, J.A., et al., 1979, *Microsurgery for Tubal Reconstruction Following Fallope-Ring Sterilization in Swine*, J. Microsurg. 1:61

© 2008 Sinclair Research Center, Inc. All Rights Reserved.

www.sinclairresearch.com
info@sinclairresearch.com
PO Box 658 Columbia, MO 65205
Tel: (573)387-4400 ▪ Fax: (573)387-4404